

Albright's Hereditary Osteodystrophy and Dementia: A Case Report

Ertuğrul Eşel M.D.¹, Munis Dünder M.D.², Fahri Bayram M.D.³, Özgül Çatakoğlu M.D.⁴,
Zuhal Candemir M.D.², M. Tayfun Turan M.D.¹, Canan Kılıç M.D.¹

ABSTRACT:

ALBRIGHT'S HEREDITARY OSTEODYSTROPHY AND DEMEN-
TIA: A CASE REPORT

Albright's Hereditary Osteodystrophy (AHO) is characterised by obesity, short stature, round face, brachydactyly, subcutaneous ossifications, mental retardation in some cases, hypocalcemia, and elevated serum parathyroid hormone (PTH) level. In this syndrome, there may be pseudohypoparathyroidism (PHP) characterised by end-organ unresponsiveness to PTH. In this report, we present an AHO case with unusual manifestation by presenting dementia which has not been previously reported.

Key words: albright's hereditary osteodystrophy, dementia, pseudohypoparathyroidism

Bull Clin Psychopharmacol 2001;11:183-186

ÖZET:

ALBRIGHT'IN HEREDİTER OSTEODİSTROFİSİ VE DEMANS:
OLGU SUNUMU

Albright'in herediter osteodistrofisi (AHO) obezite, boy kısalığı, yuvarlak yüz, parmaklarda kısalık, cilt altı ossifikasyonlar, bazen mental retardasyon, hipokalsemi ve artmış serum paratiroid hormon (PTH) düzeyleri ile giden bir sendromdur. Bu sendromda PTH'a son organ cevapsızlığı ile karakterize olan yalancı hipoparatiroidizm (PHP) bulunabilir. Bu yazıda demans semptomları ile ortaya çıkan bir AHO olgusu sunulmuştur.

Anahtar sözcükler: albright'in herediter osteodistrofisi, demans, yalancı hipoparatiroidizm

Klinik Psikofarmakoloji Bülteni 2001;11:183-186

INTRODUCTION

Albright's hereditary osteodystrophy (AHO) is characterised by obesity, short stature, dental abnormalities, round face, brachydactyly, subcutaneous ossifications, hypocalcemia, and elevated serum parathyroid hormone (PTH) level. In this syndrome, there may be pseudohypoparathyroidism (PHP) characterised by end-organ unresponsiveness to PTH. All of these features are variable. Mental retardation occurs in about 70% of cases (1). According to our knowledge, dementia associated with AHO has not been reported in the literature so far.

In PHP, the biochemical findings such as hypocalcemia, hyperphosphatemia, and elevated PTH levels are due to resistance of the target organs (bone and kidneys) to the physiologic action of PTH, but not caused by deficient PTH production. The clinical picture of convulsions, tetany, neuromuscular irritability and other hypocalcemic manifestations is similar to that seen in patients with primary hypoparathy-

roidism. However, the clinical symptoms are generally less severe than those in primary hypoparathyroidism. Hypocalcemia may not be present at birth, but usually develops in early childhood and at times is associated with mental retardation (1).

The genetics of AHO is in an unsatisfactory state. There are probably autosomal dominant, autosomal recessive, and X-linked varieties. The fact that females are affected twice as often as males supports the view that the disorder is an X-linked dominant, or sex-influence autosomal dominant (2).

CASE REPORT

A 27-year-old woman who had the symptoms such as aggressiveness, irritability, and inappropriate laughing for two years was admitted to our psychiatric unit. Moreover, she had epileptic seizures for 15 years. Although she had taken carbamazepine 800 mg/dl since her seizures started, her generalised tonic-clonic seizures continued about once or twice

¹Erciyes University School of Medicine, Department of Psychiatry, ²Erciyes University School of Medicine, Department of Medical Genetics
³Erciyes University School of Medicine, Department of Endocrinology, ⁴Erciyes University School of Medicine, Department of Neurology

Yazışma Adresi / Address reprint requests to: Associate Professor Ertuğrul Eşel, M. D., Department of Psychiatry, Erciyes University School of Medicine, Talas Road, 38039-KAYSERİ / TURKEY

Phone/Fax: (+90) 352 4375702 E-mail: ertugrulesel@hotmail.com

Kabul tarihi: 10.05.2001

a week. We learned from her relatives that she had successfully completed her elementary school, she had not had any psychiatric problem and had not exhibited any mental retardation sign up to two years before. Not until she was 25 years old did she start laughing out of the blue, rejecting to take her antiepileptic drug, showing nervousness and aggressiveness, and making absurd remarks such as mentioning about some events which had not occurred. Though she was able to keep on doing household chores, the symptoms mentioned above progressively increased.

In her physical evaluation, her appearance was unusual due to the obesity, round face and hirsutismus (Figure 1). Her pulse rate was 96/min, blood pressure was 140/80 mmHg, height was 1.51 cm, and weight was 66 kg (body mass index: 28.95). Her thyroid examination revealed diffuse hyperplasia. She had bilateral cataract in her eyes. Her external genital organs were normal in appearance.



Figure 1. Full-body view of the patient

In the psychiatric examination, it was found that she had dysarthria, poor orientation to time, blunted affect, and impaired abstract thinking. Her recent memory was also impaired, and she had some confabulations. She had no insight into her condition.

When neurologically examined, she did not have rigidity or any other parkinsonian symptoms. Her cerebellar and cranial nerve examinations were normal. The signs of Chvostek and Trousseau were negative. There was no papilledema in her fundoscopic examination.

The laboratory studies revealed the following values: Serum calcium 6.1 mg/dl (normal value: 8.8-10.8 mg/dl), serum phosphorus 8.8 mg/dl (normal value: 2.5-4.8 mg/dl), serum magnesium 0.91 mg/dl (normal value: 1.30-2.10 mg/dl), total protein 7.2 g/dl (normal value: 6.4-8.3 g/dl), serum albumin 4.7 g/dl (normal value: 3.5-5.0 g/dl). PTH level in serum was markedly high (172.0 pg/ml, normal value: 9-55 pg/dl). Serum alkaline phosphatase level was 225 U/l (normal: 120-650 U/l), and thyroid hormone and gonadotropin values were normal. Twenty-four-hour excretions of calcium and phosphorus were 37.4mg/d (normal: < 250mg/d for women) and 0.28 g/d (normal: 0.4-1.3 g/d for women), respectively.

In her radiological investigations, it was observed that she had short metatarsi and metacarpi but no subcutaneous ossifications in her hand and foot graphics (Figure 2). In her thyroid ultrasound scan, bilateral hypoechoic nodules and calcifications were found. EEG was normal. CT showed extensive bilateral symmetrical calcifications in the basal ganglia, thalamus and cerebellum (Figure 3). Her cytogenetic investigation was normal.

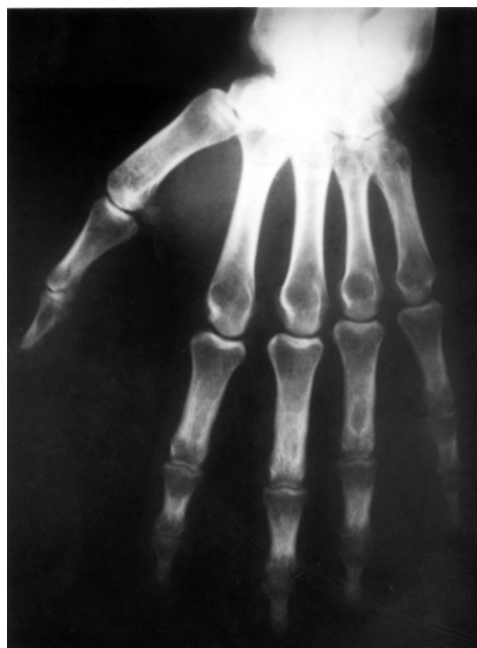

Figure 2. X-ray of the hand showing short metacarpi

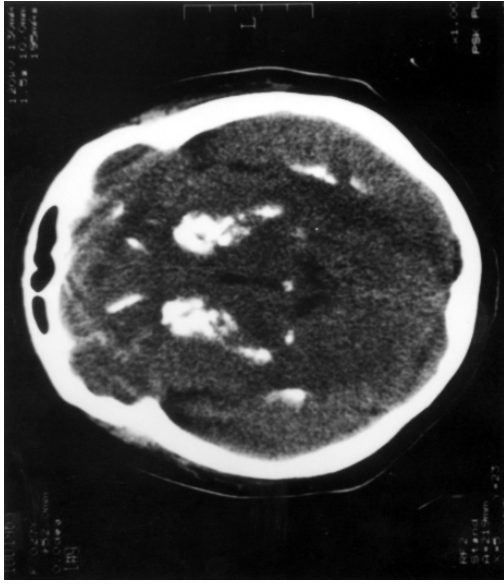


Figure 3. CT indicating extensive bilateral symmetrical calcifications in the basal ganglia, thalamus and cerebellum

In psychometric tests, Mini-Mental State Examination (MMSE) showed moderate cognitive disturbance (17 point). Her IQ was found to be low (in Wechsler Adult Intelligence Scale (WAIS), verbal: 57, performance: 39).

Since AHO is a hereditary disorder, we investigated family members of the patient. Her brother presented some of the clinical features of PHP including hypocalcemia, hyperphosphatemia, hypomagnesemia, increased PTH level and basal ganglia calcifications. He did not show any physical signs of AHO. His bone graphics and eye examination were normal. The other two members of her family (mother and sister) were normal both in appearance and in the laboratory tests.

Course: The patient was diagnosed as PHP, epilepsy due to hypocalcemia, and dementia. Since PHP was associated with other physical signs of AHO, she was evaluated as AHO. She was given calcium carbonate 6 g/d, calcitriol 0.50 µg/d, and carbamazepine 800 mg/d. Her aggressiveness, irritability and dysarthria diminished. No epileptic seizures were observed after Ca and vitamin D treatment. Ca level in serum increased to normal level (9.1 mg/dl) within three weeks after Ca treatment. Her MMSE was measured again one month after starting the treatment and found to be 20.

DISCUSSION

When the patient was admitted to the psychiatric unit, clinical and laboratory findings indicated that she had had PHP with a dementing process since the age of 25, because she met the DSM-IV dementia criteria (3). Dementia associated with brain calcifications is a frequent finding in idiopathic hypoparathyroidism (4) and postoperative hypoparathyroidism (5), and is always related to hypocalcemia. Other frequent neurologic symptoms of chronic hypoparathyroidism are epileptic seizures, extrapyramidal signs and neuromuscular hyperactivity (6). Our case had epileptic seizures but no extrapyramidal symptom or tetany.

The patient exhibited typical signs of Albright's hereditary osteodystrophy such as short stature, brachydactyly (externally and radiologically), round face, obesity, and PHP, but no subcutaneous ossification. Hypothyroidism and hypogonadism were not present in our case. Therefore, it seemed that the endocrine end-organ unresponsiveness was limited to PTH.

Although in most AHO cases, mental deterioration has been reported to start at early ages (7,8), our patient seemed to have had normal IQ until 25 years old. Therefore, dementia diagnosis was more appropriate for her. Although there are some cases whose dementia improved with calcium and vitamin D treatment in the literature (4), we may predict that the dementia will not improve in our case even if we can stop its progression with treatment, because the dementia is thought to stem from extensive brain calcifications.

In the literature, it is suggested that PHP may be inherited by autosomal or X-linked dominant mechanisms (9,10). In our case, since her brother presents some of the clinical features of PHP as well, it can be predicted that variable expressivity of autosomal dominant inheritance of PHP is present in her brother. Variable expressivity is usually a characteristic finding of the dominant inheritance. Therefore, these findings and existence of unaffected parents indicate an autosomal dominant mutation in this family.

The patient described above fully meets the diagnostic criteria of Albright's hereditary osteodystrophy and shows a new manifestation by presenting dementia.

References:

1. Jackson CE, Jackson JA. Parathyroid Disorders. In: Rimoin DL, Connor JM, Pyeritz RE, editors. *Emery and Rimoin's Principles and Practice of Medical Genetics*. 3rd ed. Edinburgh: Churchill Livingstone, 1997: 1379-1399.
2. McKusick VA. *Mendelian Inheritance in Man: A Catalog of Human Genes and Genetic Disorders*. 11th ed. Baltimore and London: The Johns Hopkins University Press, 1994: 2299-2301.
3. American Psychiatric Association. *Diagnostic and Statistical Manual of Mental Disorders*. 4th ed. Washington DC: American Psychiatric Press, 1994.
4. Stuerenburg HJ, Hansen HC, Thie A, Kunze K. Reversible dementia in idiopathic hypoparathyroidism associated with normocalcemia. *Neurology* 1996; 47:474-476.
5. Nicolai A, Lazzarino LG. Dementia syndrome in patients with postsurgical hypoparathyroidism and extensive brain calcifications. *Eur Neurol* 1994; 34:230-235.
6. Riggs JE. Neurologic manifestations of fluid and electrolyte disturbances. *Neurol Clin* 1989; 7:509-523.
7. Iozaki O, Sato K, Tsushima T, Shizume K, Takamatsu J. A patient of short stature with idiopathic hypoparathyroidism round face and metacarpal signs. *Endocrinol Jpn* 1984; 31:363-367.
8. Rogner M, Schneider H, Rupprecht E, Muller J. Pseudohypoparathyroidism-a case report. *Z Gesamte Inn Med* 1989; 44:433-436.
9. Rao VV, Schmittger S, Hansmann I. G protein G3-alpha(GNAS1) the probable candidate gene for Albright hereditary osteodystrophy, is assigned to human chromosome 20q12-q13.2. *Genomics* 1991; 10:257-261.
10. Patten JL, Johns DR, Valle D, Eil C, Gruppuso PA, Steele G, Smallwood PM, Levine MA. Mutation in the gene encoding the stimulatory G protein of adenylate cyclase in Albright's hereditary osteodystrophy. *N Eng J Med* 1990; 322:1412-1419.